

Rehabilitation Guidelines for Small-Medium (<3 cm) Rotator Cuff Repairs in Adults

About the Rotator Cuff

The rotator cuff (RTC) is comprised of four muscles that surround the shoulder joint: the supraspinatus, infraspinatus, teres minor, and subscapularis. The RTC muscles serve several purposes: 1) assist in stabilization of the shoulder joint with movement; 2) produce shoulder joint rotation and elevation.

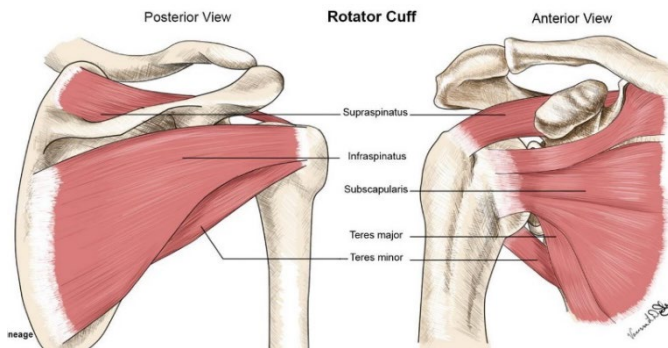


Image 1: Anatomy of the rotator cuff

Mechanism of Injury

Because of its location over the shoulder joint, the most commonly injured RTC muscle is the supraspinatus; however, all four of the RTC muscles may be involved. A RTC tear can occur from a traumatic event, such as falling on an outstretched hand, or more commonly in a chronic degenerative fashion. Full thickness rotator cuff tears do not heal on their own and tend to increase in size over time.

A RTC tear commonly results in pain around the shoulder or on the lateral side of the arm. However, this injury may also be relatively pain-free for long periods of time depending on the mechanism of injury. Following an injury, it may be difficult to lift or rotate the arm. Patients with rotator cuff disease often have difficulty sleeping or pain that wakes them at night. Patients often report weakness and fatigue of the involved shoulder.

Diagnosing a RTC Tear

There are several methods used to diagnose a RTC tear. Your healthcare provider will assess the shoulder through a physical exam. They will use evidence-based examination techniques to assess the performance of the RTC as well as the function of surrounding body regions.

Several diagnostic imaging procedures are also used to assess the RTC. Radiographic (x-ray) images are initially used to assess the bony alignment of the shoulder and evaluate for arthritis. Magnetic resonance imaging (MRI) may often be ordered to visualize the soft tissue structures, (muscles, tendons, and ligaments) and is highly accurate in diagnosing RTC injuries. Diagnostic Ultrasound also provides the opportunity to visualize the muscles dynamically to see how well they may be able to contract.

Treatment Options for a RTC Tear

Treatment options are individualized to the patient, with consideration for age, activity level, and degree of impairment to daily function. Research shows that physical therapy based conservative treatment can provide long lasting pain relief and allow you to return to your previous level of activity. Cortisone injections may be used sparingly, although many injections may be associated with negative consequences.

If surgery is indicated, repair of the RTC involves re-attaching the torn tendon back to the bone. This repair is performed by placing sutures through the involved tendons and securing them with anchors placed to the humerus. Factors that guide the decision for surgical repair include: 1) characteristics of the tear; 2) length of time from original injury; 3) sport/work requirements; 4) age; and 5) overall physical health.

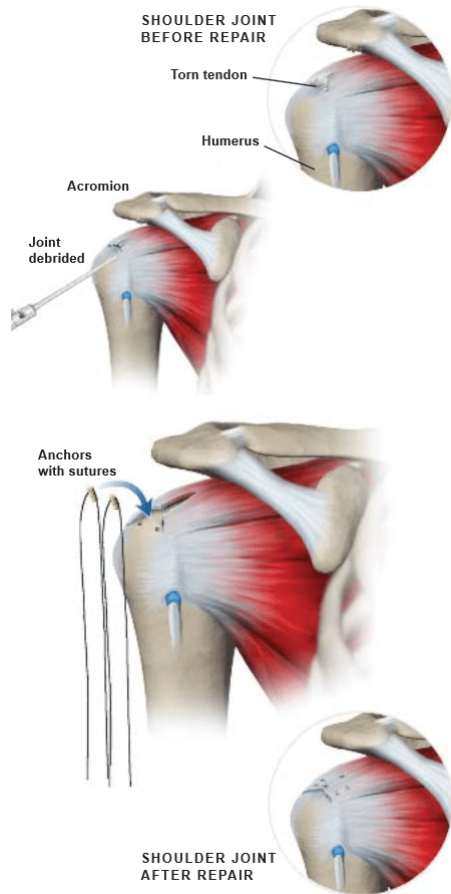


Image 2: Example of repair process

Rehabilitation Following Surgical Repair

All patients will undergo six to nine months of rehabilitation, divided into phases, focusing on meticulously progressing you back to your daily activities, hobbies, and sports. The progression through these phases is dependent on factors related to the surgical procedure performed, the surgeon's preferences, and your response to surgery. Rehabilitation is affected by the quality of the tissue being repaired. Age, tear size, muscles involved, and tendon retraction (increased distance from the torn tendon to its attachment) will lengthen the progression of rehabilitation.

Larger tears (greater than 3cm) and having multiple muscles involved creates a greater area of healing tissue. Slowing the progression through rehabilitation phases will give these tissues time to heal without additional stress; therefore, the rehab process for larger tears progresses slower to increase the odds of

adequate tissue healing. Additional precautions, like the use of a pillow between the sling and body, may be used to assist with this stress reduction. Depending on the muscles involved, there may be additional restrictions in movement in the early phases of rehabilitation to protect them from being stretched too early.

Phase I of rehabilitation focuses on decreasing pain and swelling, improving comfort, and preserving some range of motion through therapist-led mobility, where the shoulder is moved passively (without the patient utilizing recovering muscles). Phases II and III focus on developing full range of motion both passively and actively. During this phase, the patient is allowed to progressively assist in performing arm motion, until able to perform all motions without assistance. In phase III, strengthening of the RTC is initiated. This strengthening is progressed with the goal of performing all activities of daily living by the end of phase IV. During phase V, the patient transitions to developing speed and power of arm movements. It is in this phase that a progressive return to throwing program and sport-specific exercises can be initiated, under guidance of your sports medicine team.

In order to safely return to sport-specific activities, a patient must first achieve certain functional goals: 1) full range of motion; 2) greater than 90% RTC and scapular strength measurements; 3) functional shoulder complex motor control; 4) no pain with activity; and 5) physician and sports medicine team approval. Once these goals have been achieved, your sports medicine team will put you through criterion-based functional tests to determine the ability to safely return to sport. After satisfactory performance on these tests, you will progress through a return-to-sport program in order to return to pre-injury levels of performance. A referral to a strength and conditioning specialist may also be made to assist in returning you to pre-injury performance levels. Progression to pre-injury activity is time and criterion-based, and is dependent on soft tissue healing, patient demographics, and clinician evaluation.

References

1. Battista C. Medbullets Step 2/3. <https://step2.medbullets.com/orthopedics/120532/rotator-cuff-injury>. Accessed March 16, 2020. Edwards PK,
2. Edwards, PK, Ebert JR, Littlewood C, Ackland T, Wang A. A Systematic Review of Electromyography Studies in Normal Shoulders to Inform Postoperative Rehabilitation Following Rotator Cuff Repair. *Journal of Orthopaedic & Sports Physical Therapy*. 2017;47(12):931-944. doi:10.2519/jospt.2017.7271
3. Gallagher BP, Bishop ME, Tjoumakaris FP, Freedman KB. Early versus delayed rehabilitation following arthroscopic rotator cuff repair: A systematic review. *The Physician and Sportsmedicine*. 2015;43(2):178-187. doi:10.1080/00913847.2015.1025683
4. Jancuska J, Matthews J, Miller T, Kluczynski MA, Bisson LJ. A Systematic Summary of Systematic Reviews on the Topic of the Rotator Cuff. *Orthopaedic Journal of Sports Medicine*. 2018;6(9):232596711879789. doi:10.1177/2325967118797891
5. Jung C, Tepohl L, Tholen R, et al. Rehabilitation following rotator cuff repair. *Obere Extremität*. 2018;13(1):45-61. doi:10.1007/s11678-018-0448-2
6. Klouche S, Lefevre N, Herman S, Gerometta A, Bohu Y. Return to Sport After Rotator Cuff Tear Repair. *The American Journal of Sports Medicine*. 2015;44(7):1877-1887. doi:10.1177/0363546515598995
7. Mini-Open Rotator Cuff Repair. Central Coast Orthopedic Medical Group. <https://centralcoastortho.com/patient-education/mini-open-rotator-cuff-repair>. Published July 27, 2017. Accessed March 16, 2020.
8. Nikolaidou O, Migkou S, Karampalis C. Rehabilitation after Rotator Cuff Repair. *The Open Orthopaedics Journal*. 2017;11(1):154-162. doi:10.2174/1874325001711010154
9. Osborne JD, Gowda AL, Wiater B, Wiater JM. Rotator cuff rehabilitation: current theories and practice. *The Physician and Sportsmedicine*. 2015;44(1):85-92. doi:10.1080/00913847.2016.1108883
10. Sgroi TA, Cilenti M. Rotator cuff repair: post-operative rehabilitation concepts. *Current Reviews in Musculoskeletal Medicine*. 2018;11(1):86-91. doi:10.1007/s12178-018-9462-7
11. Shaffer B, Huttman D. Rotator Cuff Tears in the Throwing Athlete. *Sports Medicine and Arthroscopy Review*. 2014;22(2):101-109. doi:10.1097/jsa.0000000000000022
12. Thigpen CA, Shaffer MA, Gaunt BW, Leggin BG, Williams GR, Wilcox RB. The American Society of Shoulder and Elbow Therapists consensus statement on rehabilitation following arthroscopic rotator cuff repair. *Journal of Shoulder and Elbow Surgery*. 2016;25(4):521-535. doi:10.1016/j.jse.2015.12.018
13. Zhao J, Luo M, Pan J, Liang G, Feng W, Zeng L, Yang W, Liu J. Risk factors affecting rotator cuff retear after arthroscopic repair: a meta-analysis and systematic review. *J Shoulder Elbow Surg*. 2021 Nov;30(11):2660-2670. doi: 10.1016/j.jse.2021.05.010. Epub 2021 Jun 2. PMID: 34089878.

These rehabilitation guidelines were developed by Samaritan Athletic Medicine Physical Rehabilitation. Please be aware the information provided is not intended to replace the care or advice given by your physician or health care provider. It is neither intended or implied to be a substitute for professional advice. Call your health care provider immediately if you think you have a medical emergency. Always seek advice from your health care provider before starting any new treatment or with any questions you may have regarding a medical condition.

Rehabilitation Guideline

Rotator cuff repairs (RCR) are commonly performed following a rotator cuff tear. The protocol outlined in this document is designed for the rehabilitation of general RCR. When there are additional structures involved, or poor tissue quality, rehabilitation following surgery will need to be adjusted. Several common findings and adjustments to the rehabilitation protocol are included for consideration.

Phase I: 0-4 weeks post-surgery	
Appointments	Surgeon/Physician Assistant follow-up: 7-10 days Start physical therapy at: 7-10 days post-surgery, visits 1-2 visits per week
Rehabilitation Goals	<ul style="list-style-type: none"> ▪ Protect surgical repair ▪ Minimize inflammation and pain ▪ Progress passive range of motion (ROM) in flexion and external rotation (ER) (no ER past neutral if subscapularis was repaired)
Precautions	<p><u>Slings</u>: Worn at all times outside of treatment and performance of home exercises</p> <p><u>Mobility</u>: No active ROM, lifting, or aggressive passive ROM Limit passive ROM to flexion and external rotation</p>
Range of Motion	<p>Passive</p> <ul style="list-style-type: none"> • Flexion to 120° • External rotation to 45°
Therapeutic Interventions	<ul style="list-style-type: none"> ▪ Education on post-operative care <ul style="list-style-type: none"> - Sleeping positions while immobilized in sling: on back, with a pillow propped underneath the upper arm. Recliner chair may be recommended - Precautions with surgical repair: no active movement of arm, no removal of sling (except for prescribed exercises), no sudden movements - Clarify points of rehabilitation timeline ▪ Ice: up to 6x/day or as needed for pain (20 mins on every two hours PRN) ▪ ROM <ul style="list-style-type: none"> - Passive ROM performed by PT in flexion and external rotation, forward bow ▪ Scapular activation and mobility
Criteria for Progression to Next Rehabilitation Phase	<ul style="list-style-type: none"> • Achieve passive ROM goals: flexion- 120°; ER- 30° • Decreasing pain level
Special Considerations	<p><u>Long Head Biceps Tendon Tenodesis</u>: No straight-arm extension or horizontal abduction behind body. No loaded elbow flexion or supination for 6 weeks.</p> <p><u>Subscapularis Repair</u>: Limit external rotation ROM to neutral. No stretching into abduction</p>

Dr. McCrum: Rehabilitation Guidelines for Rotator Cuff Repair

Phase II: 4-8 weeks post-surgery	
Appointments	Physical therapy 1-2 visits per week Surgeon follow-up at 6 weeks
Rehabilitation Goals	<ul style="list-style-type: none"> ▪ Progress passive ROM ▪ Continue periscapular activation ▪ Wean from sling support ▪ Begin submaximal RTC activation
Precautions	<u>Sling</u> : gradual weaning from sling in controlled environments
Range of Motion	PROM: all planes AAROM: all planes to patient tolerance <ul style="list-style-type: none"> ▪ Dowel stretches, pulleys, band-assisted flexion and external rotation AROM: begin at week 6, all planes to patient tolerance
Therapeutic Exercises	<ul style="list-style-type: none"> ▪ Continue passive ROM and scapular activation exercises ▪ Rotator cuff activation <ul style="list-style-type: none"> – Introduce ER and IR exercise at submaximal level (~25% MVIC) ▪ (see Edwards et al, 2017, Journal of Orthopaedic & Sports Physical Therapy for details on appropriate interventions) ▪ Scapular mobility <ul style="list-style-type: none"> – Scapular Proprioceptive Neuromuscular Facilitation; serratus anterior and lower trapezius activation – Pectoral minor and latissimus dorsi flexibility ▪ Sling weaning: <ul style="list-style-type: none"> – Begin with 1 hour in home environment daily, progressing to 4-6 hours at end of week 4. – increase out of sling activity to include ADLs and light activity with the shoulder below 30° flexion at week 6.
Criteria for Discontinuation of Sling	<ul style="list-style-type: none"> • No sooner than 5 weeks. • No pain with arm resting at side • Ability to maintain mobility restrictions without sling • Tolerate out of sling activity without pain
Criteria for Progression to Next Rehabilitation Phase	<ul style="list-style-type: none"> • Full AROM • Out of sling full-time • Full return to pain-free ADLs
Special Considerations	<u>Long Head Biceps Tendon Tenodesis</u> : No straight-arm extension or horizontal abduction behind body. No loaded elbow flexion or supination for 6 weeks <u>Subscapularis Repair</u> : Limit external rotation ROM to neutral. No stretching into abduction

Dr. McCrum: Rehabilitation Guidelines for Rotator Cuff Repair

Phase III: 8-10 weeks post-surgery	
Appointments	Physical therapy 1 visit per week
Rehabilitation Goals	<ul style="list-style-type: none"> ▪ Progress to full passive ROM and increase active-assisted ROM and active ROM in flexion and ER ▪ Promote healing of soft tissue ▪ Initiate active ROM exercises
Precautions	<u>Mobility</u> : No sudden lifting, jerking or pulling motions
Range of Motion	<ul style="list-style-type: none"> • AROM: full in all planes
Therapeutic Exercises	<ul style="list-style-type: none"> ▪ Passive ROM <ul style="list-style-type: none"> - Full ROM in all planes ▪ Band-resisted RTC strengthening <ul style="list-style-type: none"> - Shoulder ER/IR - UE PNF patterns - Prone T,Y, row ▪ Pt appropriate to begin jogging at 8 weeks per PT and physician clearance
Criteria for Progression to Next Rehabilitation Phase	<ul style="list-style-type: none"> - Full PROM and AROM in all planes - Strengthening without reactive pain
Special Considerations	<p><u>Long Head Biceps Tendon Tenodesis</u>: Initiate light-resisted elbow flexion, resisted forearm supination at 8 weeks. No resisted straight-arm elevation</p> <p><u>Subscapularis Repair</u>: Initiate stretching into external rotation: achieve greater than 30° passive ROM. No resisted internal rotation until week 12. Progress to next phase with achievement of all other criteria outlined above</p>

Dr. McCrum: Rehabilitation Guidelines for Rotator Cuff Repair

Phase IV: 10-16 weeks post-surgery	
Appointments	Physical therapy 1 visit every 1-2 weeks Surgeon follow-up at 12 weeks
Rehabilitation Goals	<ul style="list-style-type: none"> ▪ Full ROM ▪ Develop proper scapular stabilization through ROM
Precautions	<p><u>Mobility</u>: no sudden lifting, jerking, or pushing activities</p> <p><u>Strength</u>: No lifting greater than 10-15lbs.</p>
Range of Motion	<ul style="list-style-type: none"> • Full PROM and AROM in all planes
Therapeutic Exercises	<ul style="list-style-type: none"> ▪ Progress resisted RTC and scapular strengthening <ul style="list-style-type: none"> - PNF, rows, DB scaption ▪ Closed chain strengthening <ul style="list-style-type: none"> - Plank weight shifts, push ups
Criteria for Progression to Next Rehabilitation Phase	<ul style="list-style-type: none"> • Full AROM • MMT 5/5 • Appropriate scapular positioning statically and dynamically • Completion of ADLs without pain
Special Considerations	<p><u>Long Head Biceps Tendon Tenodesis</u>: Progress forearm and elbow resistance exercise as tolerated to max resistance</p> <p><u>Subscapularis Repair</u>: Initiate resisted internal rotation. Progress ER stretching to full ROM. Progress all other aspects of rehabilitation as outlined above</p>

Phase V: 16-24 weeks post-surgery	
Appointments	Physical therapy 1 visit every 2-3 weeks Surgeon follow-up at 6 months
Rehabilitation Goals	<ul style="list-style-type: none"> ▪ Normalize shoulder muscular strength and power (greater than 90% LSI) ▪ Isometric or Isokinetic ER/IR strength ratio: 65-70% ▪ Progressive return to functional activities involving greater resistance ▪ Complete return-to-sport training
Precautions	<p><u>Strength</u>: Avoid activities that create substitution patterns for muscle activation</p>
Therapeutic Exercises	<ul style="list-style-type: none"> ▪ UE plyometrics as indicated for athletic participation ▪ UE and trunk coordination
Criteria for Return to Sport	<ul style="list-style-type: none"> • Mobility and strength symmetrical with opposite side • Normal scapulohumeral movement • Performance at or above normative values on UE functional tests <ul style="list-style-type: none"> - Upper Quarter Y-balance: within 90% of non-operative shoulder - Closed Kinetic Chain UE Stability: males- 20; females- 18 - Seated Shot-Put: within normative values for age/gender • No pain at rest or during activity • Physician, physical therapist, and athletic trainer clearance